

EYE STUFF THAT SHOWS UP IN PRIMARY CARE

Evan "Jake" Waxman MD PhD
waxmane@upmc.edu

92DCMS

1

▶ I have no relationships with industry to disclose.

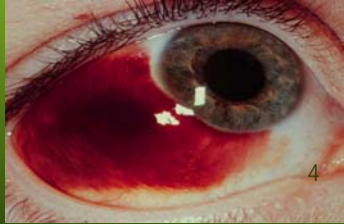
92DCMS

2

Red Eye	Chronic Vision Loss	Acute Vision Loss	Other Stuff
<u>Scary Looking</u>	<u>Pre-Op or No-Op</u>	<u>Pain & Haloes</u>	<u>Flash!</u>
<u>Icky Sticky</u>	<u>The Eye Bone's Connected to the Lung Bone</u>	<u>Not So Fugax</u>	<u>How Many Fingers am I Holding Up?</u>
<u>The Light! It Burns!</u>	<u>Up in Smoke</u>	<u>Blood & Thunder</u>	<u>Droopy</u>
<u>Red & Angry</u>	<u>The Needle Goes Where?</u>	<u>The Patient Sees Nothing The Doctor Sees Nothing</u>	<u>Marcus Who?</u>
<u>Dry & Burny</u>	<u>Sweet, Sweet Vision</u>	<u>A Lot of Nerve</u>	<u>Headaches Headaches</u>

A 68 year old man presents with a red right eye since this morning

- ▶ What questions can you ask him that will help you figure out what's wrong?
- ▶ What signs can help you know that this is or isn't something bad?
- ▶ What are reasonable treatment options?



SCARY LOOKING

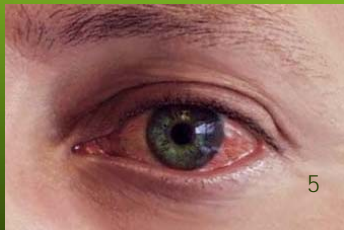9200M3



4

A 34 year old woman presents with red, irritated eyes for the past two days.

- ▶ What questions can you ask her that will help you figure out what's wrong?
- ▶ What signs can help you know that this is or isn't something bad?
- ▶ What are reasonable treatment options?



ICKY, STICKY

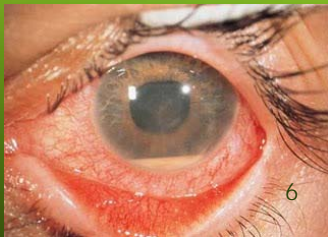9200M3



5

A 28 year old man presents with a red painful left eye over the past two days. Light makes the pain much worse.

- ▶ What questions can you ask him that will help you figure out what's wrong?
- ▶ What signs can help you know that this is or isn't something bad?
- ▶ How do you proceed?



THE LIGHT!
IT BURNS!

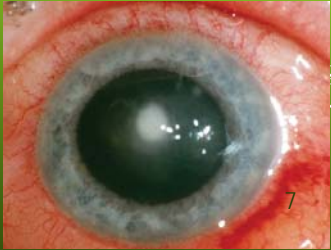9200M3



6

A 25 year old surgery resident wakes up post call with an angry left eye.

- ▶ What questions can you ask him that will help you figure out what's wrong?
- ▶ What signs can help you know that this is or isn't something bad?
- ▶ How do you proceed?

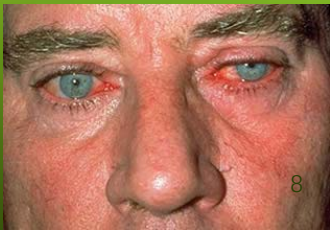

RED & ANGRY

92DCMS

A 51 year old man presents with bilateral redness and irritation for months.

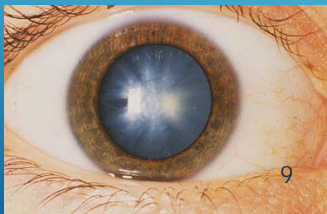- ▶ What questions can you ask him that will help you figure out what's wrong?
- ▶ What signs can help you know that this is or isn't something bad?
- ▶ How do you proceed?



DRY AND BURNY

92DCMS

- ▶ A 73 year old man recently went to see his eye doc. The eye doc told him that he has cataracts and needs to have them out. The patient has reservations.
- ▶ How would you proceed?
- ▶ Assuming the decision is made to proceed what pre-op workup needs to be done?
- ▶ Are there medications that need to be adjusted before surgery?



PRE-OP
OR
NO-OP

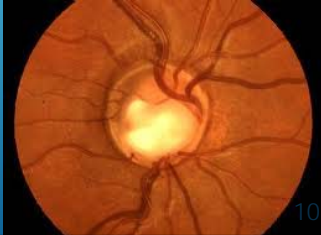
92DCMS

A 58 year old man presents with a complaint of decreased energy. He has mild COPD and open angle glaucoma. He thinks he might be depressed.

- ▶ What additional historical details might be helpful?
- ▶ What might be helpful on exam?
- ▶ Is it safe for open angle glaucoma patients to take anti-depressants with possible anti-cholinergic side effects?

THE EYE BONE'S CONNECTED TO THE LUNG BONE

92DCMS



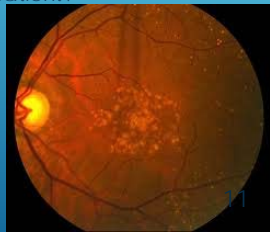10

A 72 smoker with HTN and CAD is noted to have an increase in BP at today's visit. Medications include Diovan and a vitamin he gets from his eye doc.

- ▶ What additional historical details might be helpful?
- ▶ How would you advise this patient?

UP IN SMOKE

92DCMS



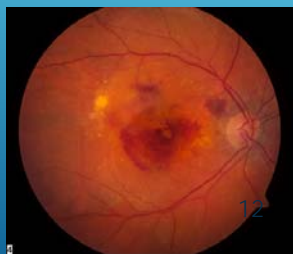
11

A 69 year old woman a slow drop in the vision of her right eye over the last few months. She's reluctant to see an eye doc.

- ▶ What additional historical details might be helpful?
- ▶ How would you advise this patient?

THE NEEDLE GOES WHERE?

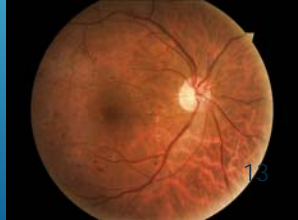92DCMS



12

You're seeing a 24 year old woman with type I DM. On ROS she makes mention of decreased vision in the right eye.

- ▶ What are your concerns?
- ▶ Your EHR shows that she's been to the eye doc every year. What additional questions should you ask?



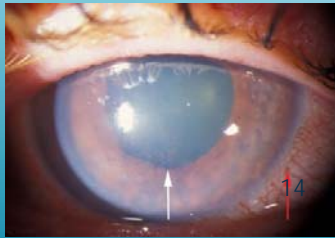SWEET, SWEET VISION

92DOMS



A 59 year old woman comes to the ED complaining of severe left eye pain since this morning. The pain has been getting worse through the day and the vision in that eye has been getting progressively foggy and dim.

- ▶ What additional historical details might be helpful?
- ▶ What parts of the eye exam might be helpful?
- ▶ What are your concerns?
- ▶ How would you proceed?



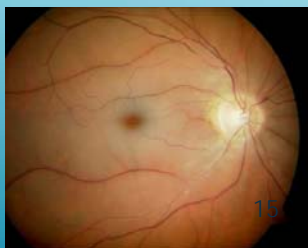PAIN & HALOES

92DOMS



A 65 year old man comes to the ED with loss of vision in his right eye that he noticed when he woke up this morning.

- ▶ What additional historical details might be helpful?
- ▶ What parts of the eye exam might be helpful?
- ▶ What are your concerns?
- ▶ How would you proceed?



NOT SO FUGAX

92DOMS

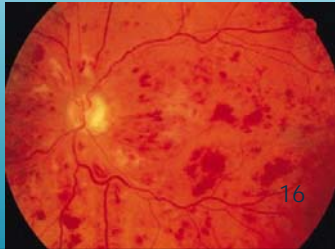


A 65 year old man comes to the ED with loss of vision in his left eye worsening over the last few days.

- ▶ What additional historical details might be helpful?
- ▶ What parts of the eye exam might be helpful?
- ▶ What are your concerns?
- ▶ How would you proceed?

BLOOD & THUNDER

92DOMS



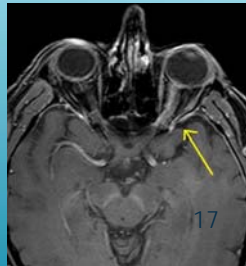
16

A 33 year old woman comes to the ED with loss of vision in her right eye worsening over the last few days.

- ▶ What additional historical details might be helpful?
- ▶ What parts of the eye exam might be helpful?
- ▶ What are your concerns?
- ▶ How would you proceed?

THE PATIENT SEES NOTHING THE DOCTOR SEES NOTHING

92DOMS



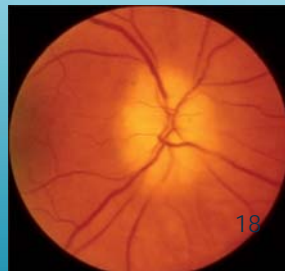17

A 65 year old woman comes to the ED with loss of vision in her right eye suddenly two hours ago.

- ▶ What additional historical details might be helpful?
- ▶ What parts of the eye exam might be helpful?
- ▶ What are your concerns?
- ▶ How would you proceed?

A LOT OF NERVE

92DOMS




18

- A 34 year old woman reports recent onset of episodes of zig-zag strobe lights in her vision.
- A 58 year old man reports flashes of light in his right eye over the last few days.
- A 71 year old woman reports episodes of sparkles of light in both eyes when she stands up quickly.

- ▶ When are the causes of photopsias?
- ▶ How do we sort them out?
- ▶ When do they represent an urgent problem?

FLASH!




92DOMS

A 63 year old man reports recent onset of 'double vision'

- ▶ What are the most important questions to ask?
- ▶ What are some of the possible causes?

HOW MANY FINGERS AM I HOLDING UP?




92DOMS

An 81 year old woman reports that her eyelids droop.

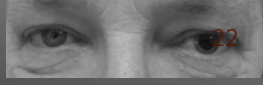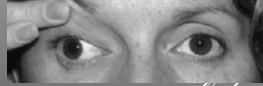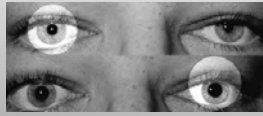- ▶ What are the most important questions to ask?
- ▶ What are the possible causes?

DROOPY



92DOMS

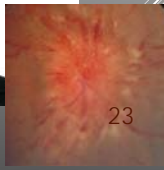
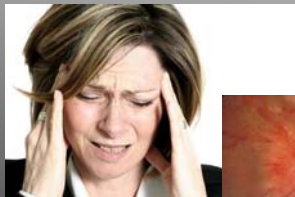
What are the really important pupil signs to look for?



MARCUS WHO?

92DOMS

When are headaches associated with eye problems?
When are eye signs associated with headaches?



HEADACHES

92DOMS

23
